

Surgical Treatment of Chronic Elbow Dislocation Allowing for Early Range of Motion: Operative Technique and Clinical Results

AU2

Duane R. Anderson, MD,* Justin M. Haller, MD,† Lucas A. Anderson, MD,‡ Samuel Hailu, MD,‡ Abebe Chala, PT,* and Shawn W. O'Driscoll, MD, PhD§

Objectives: To describe the surgical treatment and patient outcomes of chronic elbow dislocations.

Design: Retrospective review.

Setting: Two tertiary referral centers.

Patients/Participants: All patients with surgically treated chronic elbow dislocation with no associated articular fracture from January 2009 to January 2015.

Intervention: Review of patient demographics, injury chronicity, surgical technique, and patient outcomes.

Main Outcome Measurement: Clinical outcomes included elbow range of motion and complications. Radiographic outcomes included the presence of heterotopic ossification. Patient-reported outcomes included the Mayo Elbow Performance Index (MEPI) and the Summary Outcome Determination (SOD).

Results: Thirty-two patients with mean follow-up of 22 months (range, 13–41 months) were included. The mean dislocation duration was 6 months (range, 1–34 months). The mean preoperative range of motion was 8 degrees (range, 0–30 degrees). There were no infections or recurrent dislocations. One patient developed transient ulnar nerve palsy postoperatively. There were no cases of new or progressive heterotopic ossification. The mean postoperative extension was 31 degrees (range, 0–75 degrees), and the mean postoperative

flexion was 132 degrees (range, 95–150 degrees); the mean final arc of motion was 101 degrees (range, 50–140 degrees). The mean postoperative MEPI was 93 (range, 70–100), and the mean SOD score was 9 (range, 6–10). Using the MEPI, 97% (31/32 patients) had good or excellent outcome. There was no difference in flexion/extension arc or MEPI scores between groups of elbows older and younger than 17 years or dislocations less or more than 3 months.

Conclusion: This is the largest case series of surgically treated patients with chronic elbow dislocation. Using our surgical technique, 97% of patients had good or excellent outcome with a low complication rate. Open reduction of chronic elbow dislocation can be accomplished while permitting early motion with minimal recurrent dislocation risk.

Key Words: chronic elbow dislocation, pediatric, adult, surgical reduction, triceps sparing

AU7

Level of Evidence: Level IV case series. See Instructions for Authors for a complete description of levels of evidence.

(*J Orthop Trauma* 2017;00:1–8)

INTRODUCTION

The treatment of chronic elbow dislocation is a challenging problem. Historically, the results have been hampered by frequent stiffness, recurrent instability, and/or dysfunction related to violation of the extensor mechanism. Postoperative complications have led some surgeons to recommend against surgical procedures for older patients and patients who are more than 3 months out from initial injury.¹

Whether to augment the reduction with external fixation, reconstruct the collateral ligaments, and the length of immobilization or even transarticular pinning are all topics of interest in the related literature.^{2,3} Although chronic elbow dislocation is a rare problem in the developed world, it is very common condition seen by surgeons in developing countries where presentation is often delayed and dislocations are often initially treated by traditional bonesetters.

We have developed a straightforward surgical technique that allows for early elbow range of motion (ROM) with a little risk of recurrent instability. We present the operative technique and results of this surgical technique from 2 tertiary centers in Ethiopia. Our hypothesis is that our surgical technique and postoperative rehabilitation protocol allows for good patient outcome regardless of injury duration.

Accepted for publication November 16, 2017.

From the *Soddo Christian Hospital, Soddo, Ethiopia; †Department of Orthopaedics, University of Utah, Salt Lake City, UT; ‡Black Lion Hospital, Addis Ababa, Ethiopia; and §Department of Orthopaedics, Mayo Clinic, Rochester, MN.

AU3

The authors report no conflict of interest.

AU5

Presented in part at the SIGN Annual Meeting, September 2013 and at the Annual Meeting of the Orthopaedic Trauma Association, 2015.

AU4

Supplemental digital content is available for this article. Direct URL citations appear in the printed text and are provided in the HTML and PDF versions of this article on the journal's Web site (www.jorthotrauma.com).

Reprints: Lucas A. Anderson, MD, 850 W Ironwood Dr., Ste 202, Coeur d'Alene, Idaho 83814 (e-mail: Lucas.Anderson@hsc.utah.edu).

AU6

Copyright © 2017 The Author(s). Published by Wolters Kluwer Health, Inc. This is an open-access article distributed under the terms of the Creative Commons Attribution-Non Commercial-No Derivatives License 4.0 (CCBY-NC-ND), where it is permissible to download and share the work provided it is properly cited. The work cannot be changed in any way or used commercially without permission from the journal.

DOI: 10.1097/BOT.0000000000001097

PATIENTS AND METHODS

This study was a retrospective review of patients who had undergone surgical treatment of a chronic elbow dislocation without associated articular fracture performed at tertiary medical centers in Africa between January 2009 and January 2015 when the authors were using a combined medial and lateral approach (see **Table, Supplemental Digital Content 1**, <http://links.lww.com/JOT/A248>, for patient demographics and outcomes). All elbows in this series were treated without violation of the triceps and without reconstruction of the ligaments. In the years before this series, the senior author (D.R.A.) was using a single posterior approach with flaps but did not record patient data or contacts for this previous cohort. Patients were excluded if they had an associated articular fracture such as radial head, coronoid, or olecranon or did not have follow-up examinations or radiographs (see **Figures, Supplemental Digital Content 2 and 3**, <http://links.lww.com/JOT/A249> and <http://links.lww.com/JOT/A250>, for elbow radiographs before and after surgical reduction). We did not have access to the number of cases or patient data on patients excluded because of associated articular fractures. All patients treated who meet the inclusion criteria returned for follow-up radiographs. Thirty-six patients were treated for chronic elbow dislocation without associated articular fracture during the study period. Four patients had less than 12 months of follow-up and were excluded from the study.

Physical examination and anteroposterior and lateral elbow radiographs were obtained on all patients who returned for follow-up. The Mayo Elbow Performance Index (MEPI) and the Summary Outcome Determination (SOD) score were used to assess outcome at the final follow-up.⁵ For the MEPI, scores of 90–100 were considered excellent, 75–89 good, 60–74 fair, and <60 poor.⁶ The SOD score is from 10 to –10 and is assessed by the patient, with a 0 representing no change in the elbow, 10 represents a totally normal elbow, and –10 represents the worst possible outcome such as death from complications of surgery.^{5,6}

Technique

Anesthesia was routinely an ultrasound-directed supraclavicular block alone at one tertiary center (majority of cases in series) and general anesthesia at the other center and in most pediatric cases. Pneumatic tourniquets were routinely used as well as preoperative antibiotics, which was weight-based dosing of gentamicin and oxacillin at one institution and a third-generation cephalosporin at the other. The operative technique involved separate medial and lateral approaches to the elbow, while sparing the triceps mechanism. Patients were positioned supine with no arm board. Availability of intraoperative fluoroscopy was limited and not routinely used (see **Video, Supplemental Digital Content 4**, <http://links.lww.com/JOT/A263>).

Superficial Lateral Dissection

A skin incision was made along the supracondylar ridge to the level of the lateral epicondyle. From there, the incision was continued posteriorly and centered over the palpated radial head (Fig. 1). The deep lateral dissection separated the

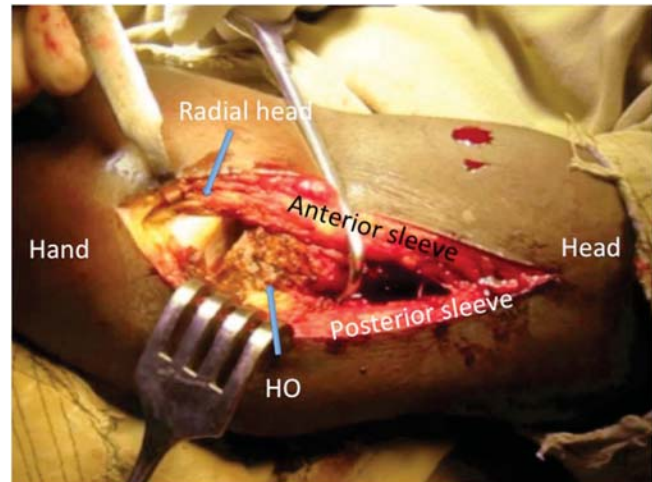


FIGURE 1. Photograph of lateral exposure of radial head/capitellum with development of anterior and posterior sleeves. Scar is debrided from the radiocapitellar joint through this exposure to allow reduction of the joint.

brachioradialis and extensor carpi radialis longus from the triceps and anconeus posteriorly along the supracondylar ridge (Fig. 2). These muscles were mobilized off the distal humerus with a Freer elevator subperiosteally in adults down to the distal ridge of the humerus. In pediatric patients, the sleeves were developed outside the periosteum so as to protect the growth plate of the distal humerus and its blood supply. As dissection is performed distally, the adherence of scar tissue was more robust, and release adjacent to the joint was facilitated by cautery. At the level of the lateral epicondyle, the effort was made to divide the soft tissues into equal anterior and posterior sleeves; the dissection was then directed posteriorly over the palpated radial head during forearm pronation/supination. Cautery was typically used to divide tissue over the radial head into anterior and posterior sleeves, which was composed of scar tissue and a small amount of anconeus muscle.

Deep Lateral Dissection

Once the radial head was visualized, dissection was carried toward the lateral epicondyle and extended along bone both posteriorly and anteriorly. During this dissection, the lateral condyle cartilage was carefully protected, and posterior dissection distal to the radial neck was avoided to protect the radial nerve. Frequently, heterotrophic ossification (HO) was encountered posterolaterally; the dissection was performed around the heterotrophic ossification to then expose the posterior aspect of the capitellum and then developed anteriorly. Finger dissection anterior to the capitellum was often effective if the elbow is dislocated less than 2 months while more chronic dislocations frequently require a 15 blade to dissect the scar anteriorly and posteriorly off the articular surfaces.

Superficial Medial Dissection

A medial skin incision was made over the medial supracondylar ridge and extended along the medial

F1

F2

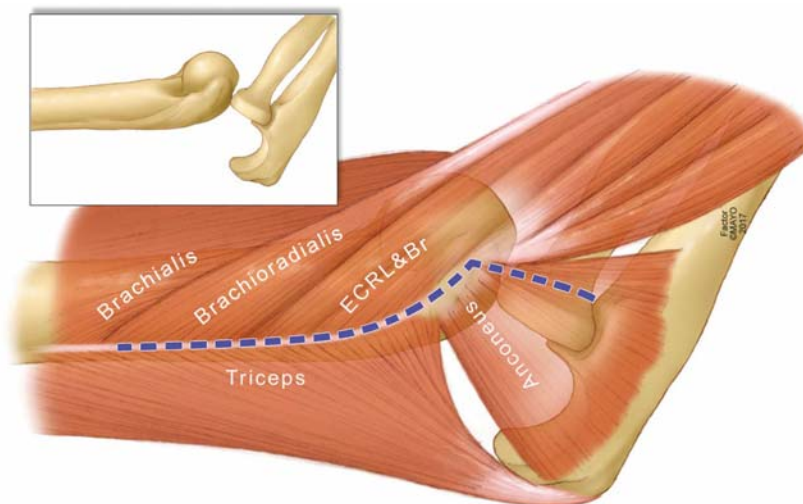


FIGURE 2. Drawing of lateral dissection with anterior and posterior sleeves illustrated with relevant anatomy. The dashed blue line illustrates the division of anterior and posterior sleeves on the lateral side, which is directed toward the radial head distally but not distal to the head and directed proximally along the supracondylar ridge. Inset image shows underlying bony anatomy.

AU12

epicondyle and 2 cm distal in line with the supracondylar ridge (Figs. 3 and 4) (see **Figure, Supplemental Digital Content 5**, <http://links.lww.com/JOT/A251>, for the development of medial-sided anterior and posterior soft tissue sleeves) The next step was identifying and mobilizing the ulnar nerve, which was safest to identify proximally outside the zone of injury and then followed distally. The nerve uniformly deviates in the direction of the olecranon dislocation, and therefore, careful dissection was required to dissect down the middle of the nerve millimeter by millimeter along its serpiginous course until the first muscular branch to the flexor carpi ulnaris was identified. Careful dissection is also paramount, as the nerve is often deeply encased in the scar. It is important to completely mobilize the nerve to protect it from traction injury during the ensuing medial dissection and allow for transposition at the end of the case.

F3

F4

Deep Medial Dissection

The brachialis was then mobilized anteriorly off of the distal humerus subperiosteally in the adult and extraperiosteally in the child. Dissection started proximally out of the zone of injury and progressed distally. Cautery was routinely used closer to the joint, as the scar was often very thick and adherent. Distal dissection on the medial side was cheated posterior so that the anterior sleeve completely contains the flexor pronator group's insertion at the distal supracondylar ridge and the medial epicondyle (Fig. 4). This soft tissue sleeve also included the insertion of the medial collateral ligament from the medial epicondyle. The posterior soft tissue sleeve at the medial epicondyle included scar, pericapsular tissue, and the triceps expansion. Anteriorly, the dissection was carried into the joint with care to stay on bone in the adult and close to bone in the child. Once the trochlear articular surface was visualized, finger or 15-blade dissection was used to release the capsule and scar at the articular margin anteriorly. The distal dissection was then carried anteriorly until all capsular tissues are released from both the medial epicondyle and condyle. The articular surface of the anterior humerus can then be fully visualized. Typically, the anterior dissection was much easier than the posterior dissection.

Once the anteromedial dissection was completed, the posteromedial dissection was commenced. The elbow was gently flexed and extended to delineate the contour of the dislocated olecranon so as to identify its articular surface. The triceps was then mobilized off of the posterior supracondylar ridge 4–5 cm, and dissection was extended to the tip of the olecranon, freeing the olecranon from the posterior humerus medially. Flexing and extending the elbow permits palpation of the olecranon; soft tissues are cut in line with the contour of the olecranon with care not to injure the articular surface.

Lateral Olecranon Dissection

Attention was then directed to the lateral elbow again; the radial head was mobilized from the posterior humeral soft tissues, but dissection was not extended distal to the radial head. Then, dissection was carried anterior to the radial head

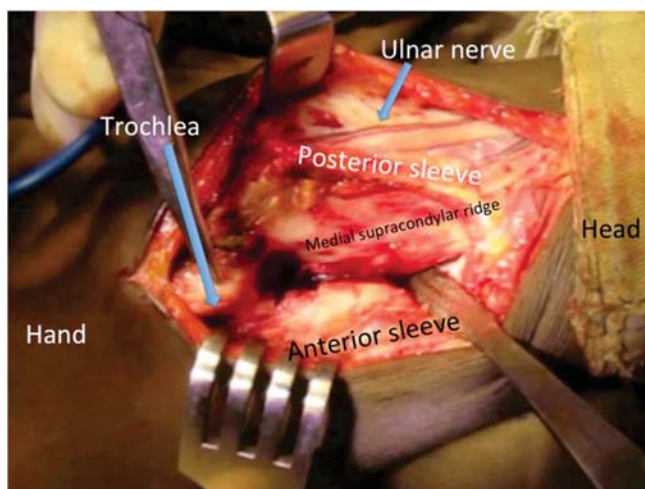


FIGURE 3. Photograph with arm in abduction and external rotation with medial exposure of humeral/olecranon demonstrating development of anterior and posterior soft tissue sleeves (Fig. 5B).

AU13

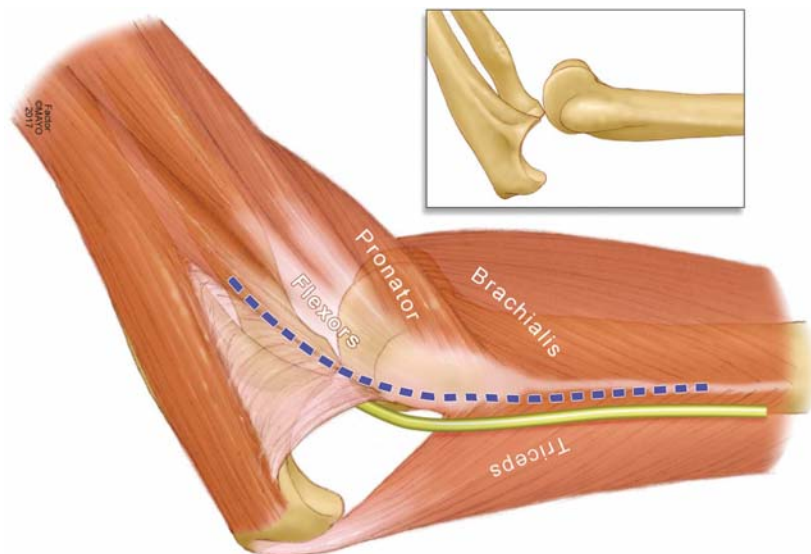


FIGURE 4. Drawing of medial dissection with anterior and posterior sleeves illustrated with relevant anatomy. The dashed blue line illustrates the division of anterior and posterior sleeves in line with the ulnar nerve, which is initially mobilized with the posterior sleeve before being dissected free for anterior transposition. Inset image shows underlying bony anatomy.

in a medial direction with the goal of locating the articular surface of the olecranon's proximal radioulnar articulation and the rest of the lateral olecranon articular surface with the humerus from the lateral side. From the lateral incision, dissection was carried toward the lateral olecranon. The elbow was flexed and extended, and the olecranon was palpated within the scar. The olecranon was repeatedly palpated, and with careful dissection, the scar adherent between the olecranon and the posterior humerus gives way, and the olecranon articular surface becomes evident. The tip of the olecranon was then mobilized and freed from any scarring to the posterior humerus. At this point, there was usually a minimal scar remaining, and the olecranon and radius are completely freed from the distal humerus. The "naked" distal humerus was then mobilized either out of the medial or lateral wound depending on the ease (Fig. 5). If performed properly, the

5

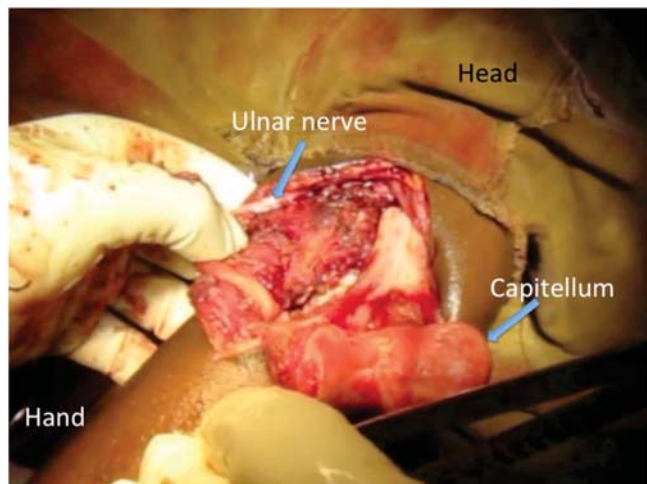


FIGURE 5. Photograph shows the complete soft tissue release of the "naked" distal humerus presenting through the medial incision and ulnar nerve freed.

periosteum in a child goes all the way down to the articular surface (see **Figure, Supplemental Digital Content 6**, <http://links.lww.com/JOT/A252>, for photographs of preservation of the periosteum in a pediatric elbow), whereas in adults, the distal humerus was basically free of soft tissue (Fig. 5). The radial head proximal to its neck was uniformly without soft tissue adherence at this point.

Olecranon Articular Scar Dissection

The olecranon articular surface is routinely covered with the adherent scar, which requires careful dissection. Once the articular cartilage margin is identified, the adherent scar is mobilized starting from 1 margin and working across the joint. The scar was elevated en masse from the cartilage with gentle leverage from a Freer elevator or gentle dissection with a 15 blade while attempting to preserve the underlying articular cartilage (see **Figure, Supplemental Digital Content 7**, <http://links.lww.com/JOT/A253>, for photographs of the scar adherent to the distal humerus) (see **Figures, Supplemental Digital Content 8A and B**, <http://links.lww.com/JOT/A254>, for photographs of olecranon and coronoid before and after debridement of the scar and HO). At some point, the mass of the adherent articular scar becomes mobilized and completely excised. It was essential to identify and remove the bands of scar running parallel to the olecranon so as to allow full congruent reduction of the olecranon in the trochlea. The depths of the olecranon fossae and coronoid fossae are cleaned out with a curette or rongeurs of scar. Any HO was removed; this was almost uniformly present adjacent to the radial head on the posterolateral humerus and was completely removed in both children and adults with aid of rongeurs (see **Figures, Supplemental Digital Content 9A and B**, <http://links.lww.com/JOT/A255>, for photographs of the distal humerus before and after removal of HO).

Elbow Reduction

Attention was redirected medially with care taken to make sure that there was adequate space between the anterior

and posterior soft tissue sleeves distally to permit passage for reduction of the humerus. This usually required deep dissection into the flexor pronator mass in line with the ulnar nerve until the first motor branch was identified. Care was taken to avoid entrapment of the ulnar nerve when reducing the elbow. The elbow was then carefully inspected for impinging soft tissue from around the olecranon to be sure that the elbow was concentrically reduced with near full extension. The triceps was uniformly tight with flexion of the reduced elbow; care should be taken to avoid forceful manipulation, as gentle incremental manipulation was usually enough to stretch the triceps. In approximately 25% of elbows, an 18-gauge needle was used to repeatedly pierce the triceps tendon percutaneously to incrementally lengthen it (see **Figure, Supplemental Digital Content 10**, <http://links.lww.com/JOT/A256>, for drawing of needle barbotage lengthening of triceps). As a caveat, generous needle barbotage can lead to significant swelling and should be avoided.

Lateral Closure

The tourniquet was released during the soft tissue repair, which reverses the hyperemia often otherwise present during flap closure. The elbow was irrigated with a dilute bleach solution made from household bleach and sterilized tap water similar to Dakin solution, which along with preoperative antibiotics likely contributes to our lack of infection in this series. Repair of the soft tissue starts on the lateral side, as the supine positioning makes lateral closure easier to start with and it is essential to ensure that the radial head is congruent with the center of the capitellum (see **Figure, Supplemental Digital Content 11**, <http://links.lww.com/JOT/A257>, for photographs of radial head/capitellum reduction before closure) (see **Figure, Supplemental Digital Content 12**, <http://links.lww.com/JOT/A258>, for photographs of lateral closure of sleeves sutured to the epicondyle through tunnels) The soft tissue envelope was repaired around the elbow as sleeves; no attempt was made to reconstruct or augment the ligaments individually (see **Figures, Supplemental Digital Content 13A–B**, <http://links.lww.com/JOT/A259>, for drawing of lateral closure with relevant anatomy). One anterior to posterior drill hole was made through the center of the lateral epicondyle using a towel clip or 2.0-mm drill. The elbow was held at 90 degrees of flexion while a #1 braided absorbable suture was used to take tissue first from the anterior sleeve (extensor origin and extensor radialis longus) through the bone tunnel and then the posterior sleeve (anconeus and extensor origin) and then another pass through adjacent tissue through the same tunnel in the direction of throw and then the suture is tied. The suture with the needle is not cut but rather continued distally as a running whipstitch in 4-mm intervals until the sleeves are fully repaired over the radial head. The whipstitch was then reversed and whipped proximally until the lateral side is completely repaired with a double repair over the radial head epicondyle extent of the elbow adding additional strength.

Medial Closure

The medial closure was undertaken with the elbow at 90 degrees of flexion and with the shoulder abducted 90

degrees and externally rotated. Once again the elbow was checked for full concentric reduction. In the majority of cases, the ulnar nerve was ultimately transposed anteriorly and submuscularly beneath the anterior sleeve (flexor pronator mass) adjacent to the joint and left superficial to the sleeves in the minority of cases.

A 2.0-mm drill hole was placed from anterior to posterior through the center of the medial epicondyle. A #1 braided absorbable suture was again used to repair the flexor pronator origin to the medial epicondyle (see **Figures, Supplemental Digital Content 14A and B**, <http://links.lww.com/JOT/A260>, for drawing of medial closure with relevant anatomy). In a similar fashion to the lateral side, the suture was passed through the flexor pronator mass/scar tissue, through the bone tunnel, and then through the pericapsular tissues/triceps expansion at the level of the medial epicondyle. The suture was passed again through the tunnel through adjacent tissue forming a double-throw stitch and tied and then continued distally as a whipstitch. The anterior and posterior sleeves are again repaired in a similar fashion to the lateral side with repair of the distal sleeves to the extent that the ulnar nerve allows and then running the stitch in a whipstitch fashion proximally until the anterior sleeve (flexor pronator mass distally and the brachialis proximally) was completely repaired to the posterior sleeve (the triceps expansion). At the level of the elbow, these soft tissue sleeves include scar, ligamentous tissue, capsular tissues, and muscle attachments. With the bony anatomy returned to its normal position, the soft tissue attachments are as close as possible to their original anatomy. Care has been taken throughout to not create individual tissue layers, which would only weaken the construct. The scar has been incorporated into the repair and adds strength. The skin was closed in a running manner, and the finger of a surgical glove was used as a drain on the ulnar side of the elbow to prevent hematoma formation.

Postoperative Protocol

We did not use wire fixation or external fixators in any of the elbows in our series, as the elbows demonstrated intraoperative intrinsic stability when closure was complete. The elbow was placed in a simple sling alone made from a gauze bandage tied around the wrist at 90–100 degrees routinely in adults. If there was any concern over elbow stability or patient compliance (pediatric patients), a posterior splint was used for the first 2 weeks. Unrestricted elbow flexion was initiated under the guidance of a physical therapist 2 days after surgery with no extension beyond 90 degrees permitted; the sling was used as an extension limit and therefore not removed for physical therapy (see **Figure, Supplemental Digital Content 15**, <http://links.lww.com/JOT/A261>, for photographs of early ROM with typical sling). Extension beyond 90 degrees was initiated 2 weeks after surgery (see **Figures, Supplemental Digital Content 16A–C**, <http://links.lww.com/JOT/A262>, for photographs demonstrating ROM at 6 weeks after surgery). One month after surgery, patients were told to carry a can with increasing amounts of water to work on extension for 10 minutes at a time 3 times a day.

We did not routinely use indomethacin for heterotrophic ossification prophylaxis except in cases in which

AUB

HO was abundant at the time of surgery and the duration of dislocation was less than 6 months. In those patients, prophylactic indomethacin was initiated immediately after surgery for 1 month. These patients accounted for approximately 25% of the cases in this series.

Statistics

We compared final ROM arc and final Mayo outcome scores between patients 17 years old and younger as compared to patients older than 17 years. Similarly, we compared final ROM arc and final Mayo outcome scores between patients with a chronic dislocation of 3 months or less with chronic dislocations greater than 3 months. We additionally compared final ROM arc and final mayo outcome scores between patients with a chronic dislocation of 1 month or less with chronic dislocations greater than 1 month. All the collected data were analyzed using a commercially available software package (Microsoft Excel; Microsoft Corp, Redmond, WA). Clinical outcomes as continuous variables were compared between the patient groups using an independent-samples *t* test.

RESULTS

Thirty-two patients (24 males) formed our study cohort, with a mean age of 25 years (range, 9–56 years) (see **Table, Supplemental Digital Content 1**, <http://links.lww.com/JOT/A248>, for patient demographics and outcomes). Twenty-six of the surgeries were performed by the senior author (D.R.A.) at Soddo Christian Hospital, Soddo Ethiopia, 5 surgeries by author S.H. at Black Lion Hospital, Addis Ababa, Ethiopia, and 1 surgery at Compassion Evangelical Hospital, Guinea, West Africa, by author S.W.O.

AU9

The mean patient follow-up was 22 months (range, 13–41 months). The duration of dislocation averaged 6 months (range, 1–34 months, SD 7 months). Preoperatively, there were no neurologic deficits present. The mean preoperative flexion/extension arc was 8 degrees (range, 0–30 degrees). The mean postoperative extension was 31 degrees (range, 0–75 degrees), and the mean postoperative flexion was 132 degrees (range, 95–150 degrees). The mean flexion/extension arc of motion at final follow-up was 101 degrees (range, 50–140 degrees, SD \pm 26 degrees). The mean final pronation/supination arc of motion was 121 degrees (range, 70–150 degrees). All patients had improvement in elbow motion. Using 100 degrees as a functional arc, 53% (17/32 patients) had functional flexion/extension arc and 78% (25/32 patients) had functional pronation/supination arc.^{7,8} The mean postoperative MEPI was 93 (range, 70–100), and the mean SOD score was 9 (range, 6–10). Thirty-one of 32 patients (97%) had good or excellent outcome as measured by the MEPI.

We first analyzed the age of patients as a factor in clinical outcome to see if this was a significant factor. We were unable to demonstrate a difference in final flexion/extension arc between patients 17 years old and younger (average 100 degrees, SD \pm 16 degrees) as compared to patients older than 17 years (average 99 degrees, SD \pm 24 degrees) ($P = 0.91$). Similarly, we were unable to demonstrate a difference in final Mayo outcome scores between

patients 17 years old and younger (average 93, SD \pm 12) as compared to patients older than 17 years (average 92, SD \pm 7) ($P = 0.75$).

Second, we analyzed chronicity of dislocation before surgery as a factor in outcome. In comparing a chronic dislocation of 3 months or less with chronic dislocations greater than 3 months, we were unable to demonstrate a difference in final flexion/extension arc (less than 3 months: average 100 degrees, SD \pm 25 degrees, vs. >3 months: average 98 degrees, SD \pm 30 degrees, $P = 0.83$). In addition, we were unable to demonstrate a difference in final Mayo outcome scores between patients with a chronic dislocation of 3 months or less (average 95, SD \pm 86) as compared to patients with chronic dislocations greater than 3 months (average 90, SD \pm 9) ($P = 0.13$). Having found no difference in outcomes with a 3-month cutoff, we decided to use 1 month as a cutoff. We were unable to demonstrate a difference in final Mayo outcome scores between patients with a chronic dislocation of 1 month or less ($n = 3$, average 96, SD \pm 6) as compared to patients with chronic dislocations greater than 1 month (average 91, SD \pm 8) ($P = 0.33$). Finally, we were unable to demonstrate a difference in final flexion/extension arc (1 month or less: average 105 degrees, SD \pm 39 degrees, vs. >1 month: average 98 degrees, SD \pm 29 degrees, $P = 0.397$).

There were no infections or recurrent dislocations or subluxations. There were no cases of new or progressive heterotrophic ossification and no cases of spontaneous elbow ankylosis in this series. There was 1 patient who developed transient ulnar nerve palsy postoperatively that fully resolved by 2 months.

DISCUSSION

Although chronic elbow dislocations are rare in the developed world, they are a common problem in developing countries. A chronically dislocated elbow joint typically results in a contracted triceps muscle, fibrosis of the joint capsule, collateral ligament contracture, possible ulnar nerve involvement, and fibrosis of the articular surface and olecranon fossa. Any intervention must address these soft tissue abnormalities. Goals of surgical treatment of chronic simple elbow dislocations include improving patient outcome through obtaining a concentric reduction and restoring functional elbow joint ROM while preserving elbow stability. As surgical technique has evolved, surgeons have become more aggressive in treating chronic elbow dislocations operatively.

Injury chronicity and patient age were previously controversial factors when considering surgical intervention for chronic elbow dislocations. There are several older studies that report poor outcomes in patients with an elbow dislocation for greater than 3 months and suggest treating these patients either nonoperatively or surgically with elbow arthroplasty.⁹ In addition to the current study, more recent studies have demonstrated good functional outcomes in patients with elbow dislocation greater than 3 months duration. Mahaisavariya et al reported mixed results in 2 patients with an elbow dislocation for 60 weeks where the patients' final arc of motion was 30 and 100 degrees.^{3,10} Naidoo reported

functional elbow ROM (greater than or equal to 100 degrees) in 39% of patients (9/23) who underwent open reduction greater than 3 months (range, 4 months–4.5 years) after initial injury.¹¹ In our series, 78% (25/32 patients) had an elbow dislocation for 3 months or greater, and we were able to restore 53% (17/32) of patients to functional ROM. Previous reports suggest that open reduction of chronic elbow dislocation in adults results in poor outcomes and that open reduction should be reserved for pediatric patients.¹² However, our case series would agree with more recent studies that demonstrate significant functional improvement in adult patients.^{12,13} Based on our case series, open reduction should remain a treatment option for patients regardless of age and chronicity of injury.

To optimize treatment goals and patient function, various surgical approaches have been described for treating chronic elbow dislocations. Speed described a posterior approach with an associated triceps V-Y lengthening for open reduction of the chronically dislocated elbow.^{6,14,15} The benefits of the V-Y lengthening include improved ROM, especially in the elbow dislocations with greater chronicity. The downside of the V-Y lengthening is possible triceps weakness, delayed physiotherapy, and increased postsurgical pain. Despite several case series reporting good results using this approach, we elected to forego V-Y lengthening to avoid the aforementioned disadvantages.^{13,16} In the past, we have used a single posterior incision with developing of large medial and lateral flaps for exposure. However, our preference now is medial and lateral incisions. Although all of our patients had severely limited motion preoperatively and significant injury chronicity, our approach of developing medial and lateral flaps allowed for adequate debridement and a less risk of postoperative hematoma while permitting early motion and did not violate the extensor complex. These results also suggest that the contracted triceps may not play as much a role in motion limitations as previously believed.

Whether it is necessary to reconstruct the elbow ligaments to maintain stability remains a topic of debate. Proponents of ligament reconstruction suggest that recurrent instability can occur without collateral ligament reconstruction once functional ROM is restored.⁹ The argument against ligament reconstruction is that it adds to the complexity of surgery and potentially prolongs restriction of motion during recovery.¹⁷ In addition, the potential for nonanatomic (non-isometric) ligament reconstruction could restrict elbow motion and can subject the articular surfaces to increased pressure and development of arthritis.^{12,13} An alternative to maintaining elbow stability without restricting the joint motion, Jupiter et al⁸ suggested using a hinged external fixator after open reduction. However, the excess cost and lack of availability in many developing countries make this option less desirable. In the current series, we created soft tissue sleeves on the medial and lateral aspects of the humerus that were repaired to their origin with bone tunnels and suture. None of the patients treated in our series developed elbow instability or had recurrent elbow dislocation. We were able to demonstrate adequate elbow stability while allowing for early motion without the need for supplemental external fixation. We believe that the use of our postoperative protocol

limiting elbow extension to 90–100 degrees has prevented recurrent instability/subluxation. Since this patient cohort, we have had 1 pediatric patient with recurrent subluxation, which we believe was because of noncompliance with the flexion protocol with premature elbow extension. The overall complaint from patients has been elbow stiffness rather than instability, and follow-up radiographs have not demonstrated recurrent instability/subluxation to date.

Importantly, our patients had improved functional outcomes with a postsurgical complication rate that was similar to other case series in the literature. Our patients had a mean postoperative MEPI score of 93 and good or excellent outcomes in all patients except 1 (31/32 patients, 97%). Mehta et al¹⁸ reported a mean MEPI of 89 with 80% (8/10) of excellent and good results. Similarly, Coulibaly et al¹⁶ reported a mean MEPI of 86 with 82% (18/22) of excellent and good results. Our reported elbow motion at final follow-up is comparable with previous case series, despite the longer injury chronicity in our patients. In addition, we did not see a significant difference in arc ROM or MEPI scores between patients regarding chronicity of dislocation (both with 1- and 3-month cutoffs for comparison groups) or with age of patient (younger than or older than 17 years). There may have been a significant difference if there had been more patients with a dislocation of a month or less; we only had 3 patients in our series who were all 4 weeks dislocated. There were no infections, deaths, and/or recurrent instability. There was 1 patient with postoperative transient ulnar nerve palsy. After this palsy, we typically transposed the nerve beneath the anterior sleeve adjacent to the joint and had no other nerve issues. Although the authors differ in opinion regarding whether to transpose the nerve submuscularly or in the subcutaneous tissue, the overall emphasis should be on careful handling of the nerve when carefully dissecting it, as it deviates in the dislocated elbow and avoid traction or incarcerating it within the joint with reduction maneuvers. Our nerve palsy rate and time to palsy resolution are similar to what other case series have reported.^{13,16} Although leaving the nerve adjacent to the joint may seem counterintuitive, this has led to no issues to date; although in the absence of long-term follow-up, we cannot give a strong recommendation between the options of (1) transposing it in the subcutaneous tissue or (2) transposing it submuscularly below the anterior flap. That said, we know that there have been complete nerve palsies when other surgeons have attempted this surgery and left the ulnar nerve in situ without transposition. We believe that this is likely due to chronic shortening and scarring about the nerve resulting from the chronic dislocation. We chose to use prophylactic indomethacin selectively and had no issues with new or progressive HO.

LIMITATIONS

There were several limitations to our study. The study population was heterogeneous and included both pediatric and adult patients as well as a range of time dislocated from 1 to 34 months. However, we noted similar satisfactory improvement in function and motion in each group, which was favorable in comparison with clinical outcomes from the

AU10

previous case series published in the literature. Second, this was a retrospective study, and we did not include data or numbers of patients excluded because of articular fractures. Third, we failed to record the condition of the cartilage at the time of the surgery, which would have been helpful to correlate with outcomes. We have experience with 1 case of chronic elbow dislocation that went on to spontaneous elbow fusion. This elbow was outside this series and was treated with a single posterior incision before adopting the 2-incision approach. When debriding the scar during the open reduction of this case, it was noted that the entire cartilage surface of the distal humerus was delaminated and only loosely attached at the peripheral periosteal cartilage junction. Furthermore, we do not have follow-up for a control group to compare with our patient group that would further demonstrate the superiority of our evolved 2-incision surgical technique. Before using the 2-incision approach, we performed a number of reductions through a single-incision approach, which used large soft tissue flaps. We anecdotally believe that a 2-incision approach counterintuitively has less soft tissue dissection/less flap development and therefore less wound issues and related complications and may be the reason for our low rate of heterotrophic ossification in our series. However, we do not have follow-up on this previous series of single-incision elbow relocations to compare outcomes with patients who underwent a 2-incision approach. Finally, we had been curious regarding the benefits of the 2-incision approach and therefore chose to follow our series after developing this technique. We unfortunately did not record the patient data on relocations performed in chronic elbow dislocations that also had fractures and therefore do not have data on elbows excluded from this study.

Strengths of the current study are that this is the largest case series of surgically treated chronic elbow dislocations in the literature. Although most surgeries were performed by the senior author (D.R.A.), we demonstrated consistent results with other surgeons when using a consistent technique that is low tech and low cost, permits early ROM with a low complication rate. In addition, we demonstrated good functional results in both pediatric and adult patients, as well as a broad range of injury chronicity indicating that this surgical technique has wide patient applicability. Finally, patients had good functional outcomes as measured by both the MEPI and SOD.

CONCLUSIONS

Our series of open reduction of chronic elbow dislocation demonstrates that early motion can be permitted with a little risk of recurrent dislocation if the triceps complex is maintained. Anatomic reduction of the bony anatomy is paramount; removing HO and scar from the articular surfaces and fossa is necessary to obtain concentric reduction and to permit full, impingement-free motion. Equally important is maintaining intact opposing flexor and extensors of the elbow

for stability, which permits early motion and may prevent elbow stiffness. Creating and then closing soft tissue envelopes around an anatomic bony reduction creates a stable environment without a need for external fixation, ligamentous reconstruction, or prolonged immobilization. In our case series, we report good and excellent outcomes in 97% of patients greater than 1 year from surgical treatment.

ACKNOWLEDGMENTS

The authors acknowledge David Factor, medical illustrator from The Mayo Clinic, for his illustrations on this article, which were an invaluable contribution to allowing the reader to understand the anatomy and surgical technique. They also acknowledge the LS Peery Foundation for their contribution in advancing orthopedic research through the University of Utah, Department of Orthopedics, in funding our research into treating this difficult problem that affects patients around the world.

REFERENCES

1. Fowles JV, Kassab MT, Douik M. Untreated posterior dislocation of the elbow in children. *J Bone Joint Surg Am.* 1984;66:921–926.
2. Jupiter JB, Ring D. Treatment of unreduced elbow dislocations with hinged external fixation. *J Bone Joint Surg Am.* 2002;84-A:1630–1635.
3. Mahaisavariya B, Laupattarakasem W, Supachutikul A, et al. Late reduction of dislocated elbow. Need triceps be lengthened? *J Bone Joint Surg Br.* 1993;75:426–428.
4. Morrey BF, Adams RA. Semiconstrained arthroplasty for the treatment of rheumatoid arthritis of the elbow. *J Bone Joint Surg Am.* 1992;74:479–490.
5. Finkbone PR, O'Driscoll SW. Box-loop ligament reconstruction of the elbow for medial and lateral instability. *J Shoulder Elbow Surg.* 2015;24:647–654.
6. Blonna D, Lee GC, O'Driscoll SW. Arthroscopic restoration of terminal elbow extension in high-level athletes. *Am J Sports Med.* 2010;38:2509–2515.
7. Sardelli M, Tashjian RZ, Macwilliams BA. Functional elbow range of motion for contemporary tasks. *J Bone Joint Surg Am.* 2011;93:471–477.
8. Morrey BF, Askew LJ, Chao EY. A biomechanical study of normal functional elbow motion. *J Bone Joint Surg Am.* 1981;63:872–877.
9. Krishnamoorthy S, Bose K, Wong KP. Treatment of old unreduced dislocation of the elbow. *Injury.* 1976;8:39–42.
10. Silva JF. Old dislocations of the elbow. *Ann R Coll Surg Engl.* 1958;22:363–381.
11. Naidoo KS. Unreduced posterior dislocations of the elbow. *J Bone Joint Surg Br.* 1982;64:603–606.
12. Elzohairy MM. Neglected posterior dislocation of the elbow. *Injury.* 2009;40:197–200.
13. Mehta S, Sud A, Tiwari A, et al. Open reduction for late-presenting posterior dislocation of the elbow. *J Orthop Surg (Hong Kong).* 2007;15:15–21.
14. Mahaisavariya B, Laupattarakasem W. Neglected dislocation of the elbow. *Clin Orthop Relat Res.* 2005:21–25.
15. Speed JS. An operation for unreduced posterior dislocation of the elbow. *South Med J.* 1925;18:193.
16. Coulibaly NF, Tiemdjo H, Sane AD, et al. Posterior approach for surgical treatment of neglected elbow dislocation. *Orthop Traumatol Surg Res.* 2012;98:552–558.
17. Arafiles RP. Neglected posterior dislocation of the elbow. A reconstruction operation. *J Bone Joint Surg Br.* 1987;69:199–202.

AU11